

# Pathologies of The Dog Associated With The Use of Choke Chains

Project submitted to The European School of Animal Osteopathy in partial fulfilment of  
the requirements for the qualification of *Diploma in Equine Manual Therapy*.

Dissertation Date: ~~January 2007~~

*8th June 2007*  
EUROPEAN SCHOOL  
OF ANIMAL OSTEOPTHY LTD  
25 OLD STEINE  
BRIGHTON  
BN1 1EL  
TEL: +44 1273 673 332  
FAX: +44 1273 673 339

**Miles Anita**

26/09/1981

*Jun 2007*

## *Members of the judging panel*

Mr. Jean-yves GIRARD, General Manager

Miss. Natacha BERTHON, General Department

Dr. Pascale SCHOENBERG

Dr. Sophie HOUBIERS

Miss. Sonja WINISTOERFER, Lecturer

Mr. Samuel COURVALLET, Dentist

Mr. Thomas GUIMBELLOT, Dentist

## Contents

Bibliography.....	Page 2-3
Introduction.....	Page 4-5
Literature Review.....	Page 6-15
Research Questions.....	Page 15
Predictions.....	Page 16
Materials and Methods used.....	Page 16-17
First Osteopathic Reports.....	Page 17-23
Second Osteopathic Reports.....	Page 23-28
Final Osteopathic Reports.....	Page 29-34
Results.....	Page 34-36
Discussion of Results.....	Page 37-43
Applications and Limitations.....	Page 43-44
Areas of Future Research.....	Page 44-45
Conclusion.....	Page 45
Questionnaire.....	Page 46
Report Form.....	Page 47

## **Bibliography**

J Small anim prac 1996 Sept;37(9):442-6

'Horners Syndrome and Ipsilateral Laryngeal Hemiplegis' Holland CT

2000 Jan,30(1);77-110

'Intervertebral disc disease' Coates JR

[www.pubmed.com](http://www.pubmed.com)

J Felin Med Search 2004 March;4(1):65-8

'Acute intervertebral disc extrusion in a cat' Lu D, Lamb CR, Wesselingh K, Targett MP

[www.pubmed.com](http://www.pubmed.com)

J Am Vet Med Assoc 1989 Aug;195(3):369-73

'Horners Syndrome in dogs and cats 100 cases' Kern TJ, Aromand MC, Erb HN

[www.pubmed.com](http://www.pubmed.com)

J Am Vet Assoc 1989 Apr15; 194(8):1096-9

'Horners Syndrome in dogs and cats 49 cases' Morgan RV, Zanoth SW

[www.pubmed.com](http://www.pubmed.com)

J Small anim prac 1995 Nov;36(11):510-2

'Horners Syndrome following cervical spinal surgery in the dog' Boydell P

[www.pubmed.com](http://www.pubmed.com)

J Small anim prac 2001 Dec; 42(12):607-10

'Horners Syndrome associated with a mandibular symphyseal fracture and bilateral temporomandibular luxation' Baines SJ, Langly-Hobbs S

[www.pubmed.com](http://www.pubmed.com)

J Emerg Med 2004 May;26(4):425-7

'A child with isolated Horners Syndrome after a blunt neck trauma' Starr BE, Shubert RA, Baumann B

[www.pubmed.com](http://www.pubmed.com)

Cornell Vet 1976 Apr;66(2):131-42

'Fibro cartilaginous emboli as the cause of ischemic Myelopathy in a dog' Greene CE, Higgins RJ

[www.pubmed.com](http://www.pubmed.com)

J neural 1980;224(2):155-7

'Intermittent Horner's Syndrome on alternate sides: a hint for locating spinal lesions'

Hopf HC

[www.pubmed.com](http://www.pubmed.com)

J Zoo Wildl Med 2000 Sept;31(3):404-7

'Caudal cervical disc protrusion in a Bengal tiger' Lambrechts NS, Berry WL

Dog notes Anne Lambermont-ford 2005-2006

The European School of Animal Osteopathy

The Well Adjusted Dog

DR. Daniel Kamen

Veterinary Notes For Horse Owners

Captain M. Horace Hayes FRCVS

Horseman's Veterinary Encyclopaedia

Will A. Hadden DVM

## Introduction

There has for a long time been a controversy surrounding the issue of dog control. While everyone agrees that dogs must be kept under control it is often difficult to know which method is for the best. The best being what is suitable for both dog and owner depending on dog size, weight, strength and trainability as well as the weight, strength, age and training ability of the owner. With so many types on the market, for example flat collars of varying width, harnesses, halti's, prong collars and anti-choke chains and leads to name just a few, all of which make claims to improve control, obedience and behaviour, the task of choosing the right one is a mind field. The owners choice of lead used is usually dictated by the dogs behaviour with most leads being manufactured towards dogs that pull. Some apply pressure to the head for control while others use the neck or shoulder regions. Surely a dog that pulls and has issues with behaviour may use these training aids to assist its own bad manners most likely at the cost of its health. **'Not only is this constant pulling uncomfortable for the person at the end of the lead but can actually damage the dogs neck and windpipe. Research done in the United States has identified that many cases of aggression were due to dogs having neck symptoms were persistent pullers on the lead. Once these dogs had spinal realignment, the aggressive behaviour significantly reduced.'**(Dog Club)

The problem of skeletal misalignment is rectified using manipulation therapies such as Osteopathy. Osteopathy involves a practitioner using a variety of techniques to rectify the misalignment. These techniques include The High Velocity Thrust, The Low Velocity

Thrust, Harmonics, Stretching and Soft Tissue Massage. The treatment is then followed by a period of rest and recuperation and a rehabilitation programme to gain the most from the treatment and prevent injury reoccurrence. Osteopathy has been being practiced on humans with great success since 1800's, it is proven in the treatment of visceral conditions as well as those of the musculoskeletal system.

The aim of this research was to establish the damage caused to the dog by the method of restraint used. The product researched into was the Choke Chain, also referred to as Check Chains or Choke Lead. The implications on the dog were the main area of concern and whether these implications were caused by miss-use of an acceptable method of restraint or whether during properly controlled use these products were able to cause damage to the dogs neck.

## Literature Review

When previous research done on the topic of damage caused to dogs by Choke Chains/Choke Leads was reviewed the results were incredibly interesting. Many papers claimed severe damage is in fact caused to the dog predominantly of the cervical spine.

**'In a retrospective study on spinal pain, injury or changes in dogs conducted in Sweden, (Hallgren 1992) found that 91% of dogs with cervical anomalies experienced harsh jerks on lead or had a long history of pulling on leads. Uses of Choke Chains was also overrepresented in this group. This strongly suggests that such corrections are potentially injurious'(Karen Overall, Clinical Behaviour Medicine for Small Animals).**

Therapist from Chiropractic backgrounds have undergone studies in this controversial subject and have turned up some enormous statistics to support their investigation.

**'During 1992 several chiropractors conducted a study of 400 dogs. The Chiropractors found back anomalies in 63% of the 400 dogs. Of the dogs that exhibited over activity and aggression 78% had spinal anomalies. Of the dogs**

**examined 91% had experienced hard jerks on a lead or had strained against them.  
(Hallgren, Chiropractor, July 1992)**

**‘The improper use of dog collars is the number one cause of cervical subluxations in dogs. Of all the region to put undue stress, the cervical region, especially the upper two cervical vertebra, is the most harmful. It is at this point that the body meets the brain. (Dr. Daniel Kamen, Chiropractor, The well adjusted Dog, P24)**

At this point certain questions needed to asked;

- Is it the misuse of a perfectly plausible training aid causing damage to the cervical region?.....
- ...Or is the damage caused by what is considered to be ‘proper use’?
- If the latter is the case then why isn’t the use of Choke Chains banned?
- Are the culprits untrained owners?.....
- ....Or are owners being badly trained in the use of Choke Chains by so called professionals?

Each of these questions were looked into fully and turned up some alarming results.

**‘Improperly trained owners, could cause extreme damage using a choke collar.**

**Yanking will cause tremendous muscle tightening in the cervical area, which in turn results in cervical subluxations, disc and other neck problems.’ (Rose Smith 2005)**



**'In 30 years of practice (including 22 as a veterinary advisor to a police dog section) I have seen numerous severely sprained necks, cases of fainting, transient foreleg paresis, and hind leg ataxia after robust use of check chains. When the practice of slamming the dog sideways with a jerk that brought the foreparts clear of the ground and two or three feet towards the handler, became popular in the 1970's the resulting painful condition was known as 'Woodhouse Neck' in this practice. Some of these cases exhibited misalignment of cervical vertebra on radiographs. My Ophthalmology colleagues have decided views on the relationship between compression of the neck, intraocular pressure and disturbances and damage to the cervical sympathetic nerve chain resulting in 'Horners Syndrome' I personally have seen a case of swollen eyes with sclera haemorrhage and a number of temporarily voiceless dogs' (Robin Walker, Vet).**

**'The cinching down of a choke chain can cause many cervical problems.'(Dr Raymond Bouloy)**

**'A 4yro greyhound is rushed to the veterinarian to determine the cause of her laboured breathing and difficulty swallowing. It was determined that improper use of choke chain had fractured her Hyoid bones in the neck that support the larynx. The trauma caused tissue swelling and bleeding cutting off the dogs ability to breath or swallow.(Judy Kody Paulsen, 2001)**

The quotes above would certainly suggest that misuse is the cause of cervical damage. The truly alarming factor here is that the damage, pain and suffering inflicted on the greyhound occurred during a training class by the professional trainer.

**'The injury to the greyhound above happened in the hands of a professional trainer. The trainer was demonstrating how to get the attention and respect of the greyhound. It took over two days for the swelling to occlude the airway to the point of asphyxia.'**(Judy Kody Paulsen. 2001)

In the 1960's and 1970's punishment based training was the most profound method for dog training. One such method was referred to as the 'Koehler method' which involved various harsh methods of training including swinging the dog from the Choke chain above ground level until it ceased to resist or became unconscious. Many other dog trainers at about this time were also using punishment methods. The 'Yank and Stomp' method was introduced by dog trainer 'Barbara Woodhouse' who had many best selling books on the subject, these books are still being sold today. The method involved the owner stopping and yanking the dog harshly to teach it not to lunge forward.

An Animal Chiropractor adamantly disagrees: **'Whiplash of the most severe kind occurs. It can also set the stage for disc disease, neuropathy, or disease to the spinal cord'**.(Sherry Fries, Chiropractor)

According to British veterinarian **Robin Walker** 'Barbara had arrived on the scene

**with here choke chains and nasty things were happening to dogs necks. I had a stream of screaming dogs arriving in my surgery with dislocated neck bones and damaged voice boxes.'**(Robin Walker, Veterinarian)

It was due to Barbara Woodhouse's training methods that the condition 'Woodhouse neck' was born. Any dog with a problem of the neck associated with its training method was said to suffer from 'Woodhouse neck'.

When the factor of the proper use of Choke Chains was looked into, there were very little positive results to unveil. Trainers who are referred to as 'Old School' still use Choke Chains and admit that a requirement when using a Choke Chain is that you tighten it around the dogs neck using a quick jerk when bad behaviour is to be rectified. In a study by 'Des Hawgood, Institute for Animal Care Education' he states that '**Most trainers I contacted do not use chains but two recommended their use, with one recommending their use on untrained dogs. One trainer advised that they should be banned altogether after nearly losing one of his own dogs to strangulation when a Choke chain locked. Only one trainer agreed they should only be used by experienced handlers. Seven thought it might be a good idea to add a warning label to each chain at the time of sale.**' During this study distributors were contacted and they replied that '**they may consider putting a warning that choke chains should only be used by experienced handlers if injury proof existed. Two other distributors were apparently unaware of any problem**'. Another alarming statement by Des Hawgood in

his study on the misuse of choke chains when referring to the need for some sort of legislation to put in place was **'the Kennel Club and RSPCA who between them control almost the total registration and welfare of dogs in this country cannot see that there may be a problem'**.(Des Hawgood, 2001)

The most commonly discovered pathologies associated with the use of choke chains are

- Cervical vertebra subluxation
- Horners Syndrome
- Severely sprained necks
- Oesophageal and Tracheal damage
- Hind limb Ataxia
- Intervertebral Disc Disease
- Wobblers Syndrome
- Cases of fainting
- Transient foreleg paralysis
- Recurrent Laryngeal nerve paralysis

EUROPEAN SCHOOL  
OF ANIMAL OSTEOPATHY LTD  
25 OLD STEINE  
BRIGHTON  
BN1 1EL  
TEL: +44 1273 673 332  
FAX: +44 1273 673 339

### **Intervertebral Disc Disease**

**'Neurological dysfunction is the most common clinical manifestation of intervertebral disc disease.'**(Coates JR, 2000)

**'A 5yro male cat had acute left Hemiparesis and Horners Syndrome. MRI revealed loss of normal signal from the neuleous populous of intervertebral disc c3/c4. Narrowing of the ventral Subarachnoid space and slight dorsal displacement of the spinal cord at the same level. Presumptive diagnosis was spinal cord oedema associated with intervertabral disc extrusion. A traumatic actiology was suspected.'**(Lu D, lamb CR, Weselingh K, Targett MP, 2004)

### **Horner's Syndrome**

Horner's syndrome is not uncommon in dogs, horses, cats or humans. The symptoms include a sunken eye with a small pupil and a prominent third eyelid. The eye has both sympathetic and parasympathetic innervations. If the sympathetic impulses to the eye are blocked there would be an over balance of parasympathetic innervations. This causes the pupil to constrict and all of the muscles of the eye to relax. The nerve that carries sympathetic innervations to the eye travels down the spinal cord from the brain, emerges in the chest cavity and then travels back up the neck along the Carotid Artery and Jugular Vein through the middle ear and into the eye. Horner's Syndrome is associated with brain tumours, spinal cord injury in the neck, thoracic tumours, injuries to the neck from fighting or constrictive trauma and middle ear infection.

**'74 dogs and 26 cats with Horner's Syndrome were examined. The cause of Horner's**

**Syndrome could not be determined in 50% of dogs and 42.3% of cats. The important causes of Horner's Syndrome in dogs and cats were trauma to the Brachial Plexus.' (Kern TJ, Aromando MC, Erb N 1989)**

**'Medical records of 49 dogs and cats with Horner's Syndrome were reviewed, Causes included head, neck and chest trauma.'(Morgan RV, Zanotti SW, 1980-1986)**

**'Two Dobermans exhibited Horner's Syndrome after surgical treatment for cervical spondylpathy.'(Boydell P, 1995)**

**'Interruption of the post ganglionic neuron in the sympathetic pathway is reported to be a cause of Horner's Syndrome in the cat.'(Baines SJ, Longly-Hobbs S, 2001)**

**'A case of Horner's Syndrome in a 5yro Child after a blunt neck trauma to the neck.'(Starr BE, Shubert RA, Baumon B, 2004)**

**'Horner's Syndrome developed in a 6yro female black Labrador 24hrs after a days exercise. Gross and microscopic examination revealed the presence of ischemic infarct in the c6 segment of the spinal cord.'(Greene CE, Higgins RJ, 1976)**

**'A patient with cervical intramedullary epedymoma is described who exhibited**

**Horners Syndrome on alternate sides, pharmacological study demonstrated damage to the pre-ganglionic sympathetic neurons.’(Hopf HC, 1980)**

**‘Horners Syndrome is described in three cats associated with wounds to the ventrolateral neck.’(Holland CT, 1996)**

### **Hind Limb Ataxia**

**‘A young adult male Bengal tiger was presented with hind limb ataxia. Cervical and lumbar myelography revealed compression lesion of the spinal cord at c6/c7.’(Lambrechts NE, Berry WL, 2000)**

The above scientific findings reveal damage to the cervical region is the main cause of many medical conditions stemming from damage to the cervical region all of which can be associated with restriction and trauma like that associated with the use of choke chains.

### **Wobblers Syndrome**

**‘There may be more than one cause of wobblers, but compression of the cervical spinal cord has definitely been shown to cause the symptoms in many cases. The**

**compression may be developmental (congenital) or acquired (injury).'(Will A Hadden DVM)**

**'The Wobbler Syndrome results from damage to the nerve trunks passing along the spinal cord in the neck. This is usually the result of injury to the bony canal through which the spinal cord passes on its way to the brain.'(Captain M. Horace Hayes FRCVS)**

### **Research Questions**

Does the use of choke chains increase the risk of damage to the dogs cervical region?

Is there a relationship between the use of a choke chain, cervical pathologies and excitable or nasty behaviour?

Are the cervical pathologies found in dogs, associated with the use of choke chains, rectified with Osteopathic treatment?

Do cervical pathologies reoccur in dogs if choke chain use continues?



## **Predictions**

Based on existing research predictions for further research could be made. The association between choke chains and cervical damage in existing journals spoke volumes, therefore cervical lesions were expected to be found. An association between dog behaviour and cervical lesions were also documented, so an improvement in excitable or nasty behaviour after Osteopathic treatment would also be predicted.

## **Materials and methods used**

- Large dogs, pointers, Labradors
- Walked at least three times a week using a choke chain/check chain
- Dogs were all aged between one and six years old
- Dogs were observed at both walk and trot to assess the dogs in dynamics

The owners were asked to give a detailed history of each dog, they were asked about the dogs age, breed, height, medical history, any previous accidents, any leads the dog has been walked on in the past other than a choke chain, where they are exercised and how

often, has the dog every shown any signs of aggression or over excitement, where the dogs sleeps, i.e. in the house or in a kennel?.

## **Osteopathic Reports**

### **First Examinations**

*Dog A:* 2yro Pointer bitch, been with current owner five weeks. Rescued from a kennels only previous history known was that dog was exercised from a push bike. Current owner felt dog always looked hunched up. Dog didn't used to pull on the lead but now pulls very badly. Dog is very disobedient and very excitable. Hopes to make a shooting dog but behaviour is proving to be a problem. Walked daily on a choke chain around relatively flat fields, on occasions when dog had been let off the lead it ran off for hours at a time. Dog generally stands with right hind limb in engagement. Dog lived in a kennel outside as again behaviour proved a problem. Recently a significant drop in weight had been noticed and put down to being in new surroundings.

Dynamics: At walk dog strained very hard at the lead, making choking noises. Dog looks very tight in the shoulder region and in the hindquarters. At trot the dog is showing incapability to trot, jumping along keeping both hind legs together. Straining very hard at the lead causing its head to be pulled towards owner, the dogs right. Dog bounded across the path of the owner from left to right as lack of control over the dog is apparent.

Palpation and Testing: Tight in shoulder muscles, resisting full extension of Humeroradial joint and scapulohumeral joint. Over developed Gluteals, under developed hamstring group ( semi-membranous, semi-tendonose, biceps femoris ). Reduced ROM in left Ileum, right Ileum showing excessive movement.

Treatment: IVT of right Ileum

LFR of Atlas

L4 LFR

L3 RFR

***Dog B:*** 2yro pointer bitch, believed to be from same litter as dog A, had been with current owner only five weeks. Rescued from a kennels no previous history known. Dog is walked daily on a choke lead around relatively flat fields, dog could not be let off lead as runs away. Dog is very excitable and disobedient. Owner hopes to train for shooting but behaviour proving to be a problem. Dog lived in a kennel as behaviour too bad to live in the house. Dog pulls very badly on lead causing choking noises.

Dynamics: At walk, the dog is lead from the owners left, pelvis is carried to the left, shoulders leaning to the left as dog pulls and strains against the lead, right curve throughout the thoracic region, dogs head was pulled to the right.

Palpation and Testing: Tight in shoulder muscles resisting full extension of Humeroradial

joint and Scapulohumeral joint. Muscular tension through erector spinae.

C3 RHR C4 LHR showing reduced ROM to the right.

T7/T8 LFR

L2 LFR

Treatment: C3/C4

T7/T8

L2

Dog was given a massage throughout thoracic spine

***Dog C:*** 5yro black Labrador bitch, Gun dog, owned by the same owner since a puppy.

Lives in the house although lived in a kennel until recently, walked three times a week on a lead for obedience training, dog pulls quite hard and sometimes choked itself, dog is not always very obedient and requires the aid of an electric shock collar to keep its attention, this was a recent addition as for four seasons the dog had pulled very hard on the lead making a days shooting quite a chore, and when let off the lead the dog was not very obedient. Dog had lived whole life on a farm and had in the past collided with a quad bike a couple of times but didn't ever need veterinary attention.

Dynamics: At walk the dog strained at the lead and its head was pulled to the right, the dog showed stiffness in the hindquarters. At trot the dog pulled so hard it was choking

and out of the owners control. Dog carried its pelvis to the right and appeared to have a rolling action of the forehand.

Palpation and Testing: Reluctant to fully extend humero-radial joints, crepitation in left elbow joint. muscular spasm mid-thoracic region and lower lumbar region.

C3 RHR C4 LHR showing reduced ROM to the right

Muscular spasm in mid thoracic region

T 7/T8 LFR

L4 RFR

EUROPEAN SCHOOL  
OF ANIMAL OSTEOPATHY LTD  
25 OLD STEINE  
BRIGHTON  
BN1 1EL  
TEL: +44 1273 673 332  
FAX: +44 1273 673 339

Very greasy dull coat containing a lot of dead hair.

Treatment: C3/C4

T7/T8

L4

Mobilisation of left elbow : Harmonics and gentle stretching to regain extension, severe crepitation in left humeroradial joint.

**Dog D:** 6yro Labrador cross, domestic pet. Lived with current owner since a puppy. No previous accidents or medical history. Dog was walked five times a week on a choke chain and was let off the lead during walks to run around fields. Dog had generally very obedient behaviour although did pull hard enough on the lead to make choking noises.

Dynamics: At walk the dog walked with a stiffness in the hindquarters and with a tendency to lean to the left with the shoulders. Dog preferred to canter rather than trot, holding pelvis to the left with left leg engaged.

Palpation and Testing: Muscular spasm in early thoracic region and lower lumbar. Very tight in left Gluteal muscles. Tension in the tail when lifted, the dog looked very unhappy at this test. Dull greasy coat.

IVT right Ileum

C2 RHR C3 LHR reducing ROM to the right.

Treatment: C2/C3

Right Ileum

***Dog E:*** 4yro pointer bitch had had one litter of puppies 8 months previous. Owned by the same people since a puppy. Walked daily on a choke chain in relatively flat fields. Dog showed good behaviour and obedience when in the house although pulled very hard when on a lead. Dog lived in the house.

Dynamics: At walk dog walked relatively straight but strained at the lead. At trot dog pulled very hard running across the owners path from one side to another, dog trotted with hind legs very wide apart and had a 'waddling' appearance. Dog made choking

noises as it pulled so hard.

Palpation and Testing: Dog showed muscular spasm in lower neck, mid thoracic and lumbar regions. Resisted full extension of right shoulder, crepitation in right Humero-radial joint. Dog had a very flat appearance to its top line.

Treatment: C1 RFR

C5 LHR/C6 RFR reducing ROM to the right

T6 RFR

L2 RFR

L4 LFR dog yelped on palpation, after treatment the dog stood for some seconds with its back arched.

Very tight in extension of right shoulder

***Dog F:*** Syro yellow Labrador dog, walked daily on a choke chain, exercised usually on roads and some tracks. Lives in the house, is generally very well behaved. Only pulls on the lead at the sight of other dogs or cats. Had never shown any signs of aggression or particular over excitement. Dog always lead from owners left hand side.

Dynamics: At walk dog shows pelvis being carried to the right, dishing of left fore. At trot pelvis carried to the right, left hind limb being carried in adduction. Dishing of the left fore was more pronounced at trot.

Palpation and Testing: Dog showed muscular spasm in mid thoracic region and lumbar region. Dog had greasy rough coat.

Treatment: C4 RHR  
C5 LHR  
Ileum RHT  
L4 LFR

Once treatment of L4 had taken place the RHT of the Ileum was dramatically reduced. Tightness of gluteal muscles was treated with soft tissue massage techniques to relieve muscular spasm.

### Second Examinations

#### ***Dog A***

Observations since last examination: Dog had gained a little weight. Dog stood with left hind in engagement less often. Dogs behaviour on the lead had improved the day after treatment, but then over the next few days reverted back to pulling hard at the lead again.

Dynamics: At walk the dog strained hard on the lead showing a stiff, tense gait. At trot the dog was able to use each hind limb individually not jumping along with both hind limbs, although as dog got excited it showed it found it easier to propel itself along in this manner.



Palpation and Testing's: Tight through shoulders showing reluctance to full extension. Gluteal muscles have a lower level of tone and Hamstring group have a higher level of tone. IVT of right Ileum had resumed by approximately 80%. Some muscular tightness present through lumbar region. Dog still showing slight right IVT of the Atlas but was greatly improved.

Treatment: LFR of Atlas  
IVT of right Ileum  
Massage given over Thoracic and Lumbar spine

***Dog B***

Observations Since Last Examination: Dog was quiet and slept for a long period after treatment.

Dynamics: Dog still pulled very hard at the lead and had its head continuously pulled to the right in both walk and trot in order for the owner to try and maintain some control. The dog still carried the Ileum to the left in a LHT and in a left IVT as it scuttled along falling out through the left shoulder causing a right bend through the thoracic region.

Palpation and Testing's: ROM in the cervical region to the left was still reduced and no significant improvement had been made. Muscular spasm was still present throughout the thoracic region and T7/T8 showed a LFR pathology. Reluctance to extend the

Scapulo-humeral joints and Humero-radial joints was still apparent as was the muscular tension through out the shoulder region.

Treatment: C3/C4

T7/T8

Soft tissue massage was applied to the Thoracic and Shoulder regions

### ***Dog C***

#### Observations Since Last Examination:

Coat condition improved, dead hair seemed to go and dogs coat had a shine within 48 hours of treatment, however owner considered that the coat condition was becoming more greasy again as time progressed from first treatment to second.

Dynamics: Dog still appeared to have a rolling action in the forehand at trot, Ileum still carried to the right although not to such a noticeable degree.

Palpation and Testing's: Cervical ROM reduced to the right at level of C3/C4, muscular spasm at level of L4 in conjunction with RFR.

Treatment: C3/C4

L4 After the treatment of L4 the RHT of the Ileum had greatly reduced.

Massage to the Lumbar and Gluteal regions was applied to relax spasms created in compensation for the L4 pathology.

***Dog D***

Observations Since Last Examination:

Condition of coat improved, coat had a shine after treatment

Dynamics: Dog walked quietly at owners side in walk, showing slight abduction of right hind limb. Dog carried the ileum in a RHT at trot with abduction of right hind limb and adduction of the left hind limb giving the appearance of the dog swinging its legs to the right. Dog pulled hard at the lead during trot.

Palpation and Testing's: Dog had tight sore muscles bilaterally at base of cervical region. Mid thoracic region showed muscular tightness in conjunction with T7, Tightness in right Gluteals. Tension in the tail had resumed.

Treatment: Base of neck treated with soft tissue massage techniques bilaterally to resume ROM.

T7 treated for RFR massage techniques relaxed spasm

Gluteal area treated with soft tissue massage techniques as right Gluteals

Tight and showing soreness.

***Dog E***

Observations Since Last Examinations:

After the first treatment it was noted that the dog would roll around on its back scratching which it didn't do before. The dog slept for a long time after treatment.

Dynamics: The 'waddling' action of the rear end appeared to be less obvious than it had been in the first dynamic examination. Dog still pulled hard at the lead and caused itself to choke, At walk the dog was straight in its movement but at trot was still running from side to side, the owner had the dog on a very short lead as she felt she was lacking control otherwise. The dog made a much rounder shape over its back than it had during the first dynamic examination.

Palpation and Testing's: Muscular spasm in the mid thoracic region in conjunction with

T6 RFR

L2 RFR

C5/C6 RHR reduced ROM to the right

Extension of right shoulder improved, no crepitation in right Humero-Radial joint.

Dog had a much rounder, arched shape to its back.

Treatment: C5/C6  
T6 RFR  
L2 RFR  
Soft tissue massage of back

***Dog F***

Observations Since Last Examination: The condition of the dogs skin improved. The owner noticed that the dog found getting into the car easier than it had previously.

Dynamics: At walk dog was much straighter. At trot the dog still showed RHT of Ileum but as noticeable as in the previous examination. Dishing of the left fore was still apparent.

Palpation and Testing's: Muscular spasm in the lumbar region in conjunction with LFR of L4. Palpation of the left forelimb uncovered a sore area between digits which may prove to be the reason the dog dished this limb. Dog was taken to the vet for treatment of the sore area. ROM was still slightly reduced to the right in the mid cervical region.

Treatment: C4/C5  
L4 Soft tissue massage techniques were applied to the muscles of the Thoracic and Lumbar spine to relieve spasm.

## **Final Osteopathic Examinations**

### ***Dog A***

**Observations Since Last Treatment:** The hunched appearance of the dog no longer remained and the dog was using both hind legs individually for propulsion rather than hopping along using both hind limbs at once.

**Dynamics:** At walk the dog showed much better manners walking by the owners side and not pulling too hard. At trot the dog pulled fairly hard at the lead but did so in a straight line and stayed by the owners side not darting from side to side. The IVT of the left Ileum appeared to have been resolved as the dog used both hind limbs equally and was straight in its gait.

**Palpation and Testing's:** The Hamstring muscles were now showing a good level of tone and the Gluteals had reduced in tone. The right IVT of the Atlas was present although there was approximately an 80% improvement from the first examination.

**Treatment:** IVT of Atlas

EUROPEAN SCHOOL  
OF ANIMAL OSTEOPATHY LTD  
25 OLD STEINE  
BRIGHTON  
BN1 1EL  
TEL: +44 1273 673 332  
FAX: +44 1273 673 339

## ***Dog B***

Observations since Last Treatment: Dog didn't pull so badly on the lead for a few days after treatment but resumed bad behaviour on the lead during the next five days, this was still an improvement since the first examination.

Dynamics: The dog appeared not to be pulling on the lead as much as in previous examinations but still it still couldn't be said that the dog was walking quietly by the owners side. The dogs head was still being pulled to its right in order for the owner to keep control. As the dog wasn't pulling so hard it wasn't falling out through the left shoulder so badly and the IVT of the left Ileum had resumed.

Palpation and Testing's: ROM to the left in the mid cervical region had improved but still showing a reduction in mobility. Muscular spasm in the mid thoracic region had greatly reduced, showing approximately 80% improvement, extension of the shoulders had improved by approximately 60%. The LFR of T7/T8 had resumed. The musculature of the dog had a softer more pliable feel.

Treatment: Mid cervical C3/C4

Entire Thoracic region treated with soft tissue massage techniques.

### ***Dog C***

Observations Since last Treatment: Again the condition of the coat had improved and this time remained. Dog was tired and slept a lot the evening of treatment.

Dynamics: Dog still pulling quite hard on the lead although the owner felt not as badly as it used to. The RHT of the Ileum had resumed and the dog moved with an improved straightness throughout its body.

Palpation and Testing's: Reduced ROM to the right at the level of C3/C4. Muscular spasm present in mid thoracic region at the level of T7/T8. Apart from pathologies just noted musculature of the dog was soft and pliable and ROM in joints bilaterally was fairly even, the dog had shown great improvement since the first examination.

Treatment: C3/C4

T7/T8 Soft tissue massage

### ***Dog D***

Observations Since last Treatment: Condition of the coat was good after treatment and appeared very clean, no dust or scurf.

Dynamics: RHT of the Ileum had resumed as the dog walked and trotted with a straight



action. Dog showed good straightness throughout the body during both walk and trot.

Palpation and Testing's: Slight muscular spasm in the thoracic region. Very slight reduction in the ROM of the lower cervicals. The dog otherwise showing equal bilateral movement of joints and its musculature was soft and pliable with a good level of tone.

Treatment: Lower cervical region C4/C5

Soft tissue massage techniques to thoracic region

### ***Dog E***

Observations Since Last Treatment: Dog still rolling about scratching its back. Owner reported to feel that the dog was happier and had noticed that it found getting down the stairs much easier than it had previously. Behaviour on the lead had not really improved throughout treatments.

Dynamics: At walk the dog showed straightness throughout its body. At trot the dog was still pulling hard and so had its head pulled to its right causing the dog to be travelling out through the left shoulder. The hind limb action of the dog showed a huge improvement from the first dynamic examination, the waddling action the dog had adopted had resumed and the dog appeared to have more flexion of the hind limbs when at the trot. The flat, hollowed appearance had also resumed as the dog was showing a roundness to the back.

Palpation and Testing's: Reduced ROM to the right in the lower cervical region, C5/C6 but had improved since the second treatment. Dog showed a small amount of spasm in the thoracic region. Dog otherwise had a good even tone throughout its musculature and showed bilateral evenness of joints during testing. Dog showed full extension of the back during reflex test.

Treatment: C5/C6

Massage techniques used over entire back for muscular tension in thoracic region and as a preventative measure as dog had had a lot of pathologies present at first examination.

### ***Dog F***

Observations Since Last Treatment: Dogs coat still showing improvement in condition, dog still getting into the car and up steps and stairs easier. At second examination it had been discovered that the dog was suffering from a sore between second and third digits, the dog had received treatment from a vet.

Dynamics: Dog showed good straightness throughout the body in walk. At trot the dishing of the front left limb had resumed by approximately 90%. The RHT of the Ileum had also greatly improved.

Palpation and Testing: Palpation of the sore digit showed no pain reaction. Testing of the

shoulder joints showed a restriction in the left shoulder. Gluteal muscles on the right had an increased level of tone and L4 still in a LHR . C4 RHR/C5 LHR. The restriction of the left shoulder and increased tone in gluteal muscles were most likely to be compensatory to the sore digit.

Treatment: L4 LHR

C4/C5

Entire dog was given a massage to relieve muscular spasm.

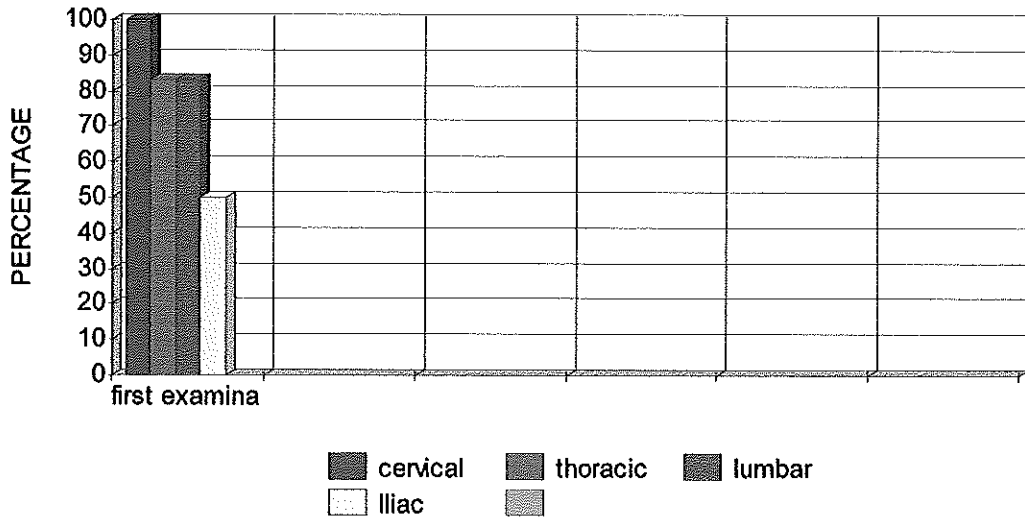
### Results

The results of the above research highlights some very interesting points. The subject of choke chains, and the damage incurred by the them, can be clearly seen as 100% of the dogs examined had cervical lesions, 83% had thoracic lesions,83%had lumbar lesions and 50% had Iliac lesions at the time of the first examination. I believe that where 100% were still showing the presence of cervical lesions and 33% were showing the presence of thoracic lesion, all be it that the severity of these lesions had reduced at the time of the final examination, the reoccurrence of these lesions was owing to the continued use of the choke chains.

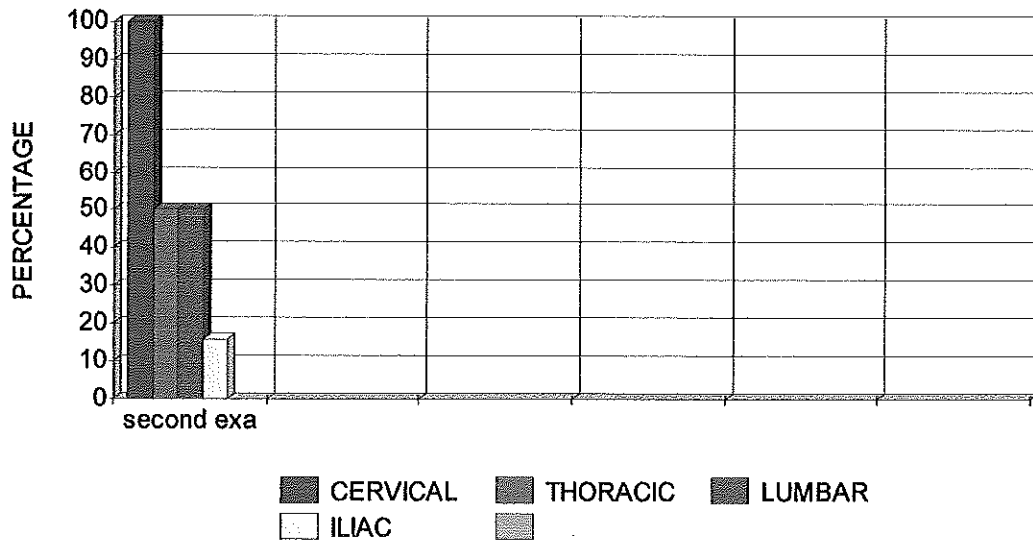
Good results were seen with regard to the other lesions that were present in the dogs. Dog B had a severe IVT of the Ileum believed to be the result of being hit by a push bike, by the final examination Dog B was using both hind limbs equally and its stride length had improved immensely. Of the dogs used 83% had Lumbar lesions at the first

examination and only 16% had Lumbar lesions at the final examination showing a 67% improvement. At the final examination none of the dogs were suffering from Iliac lesions showing a 100% improvement.

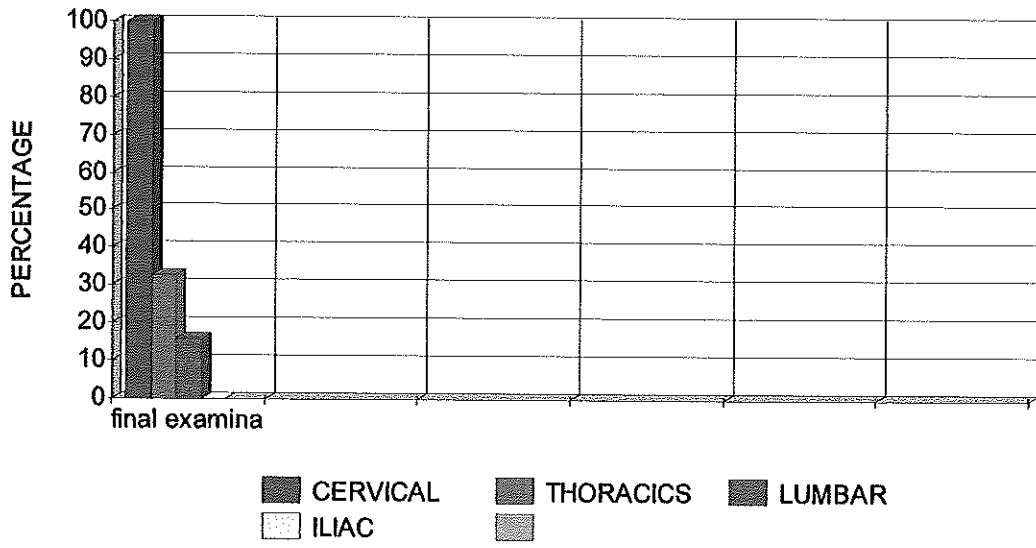
### RESULTS OF FIRST EXAMINATION



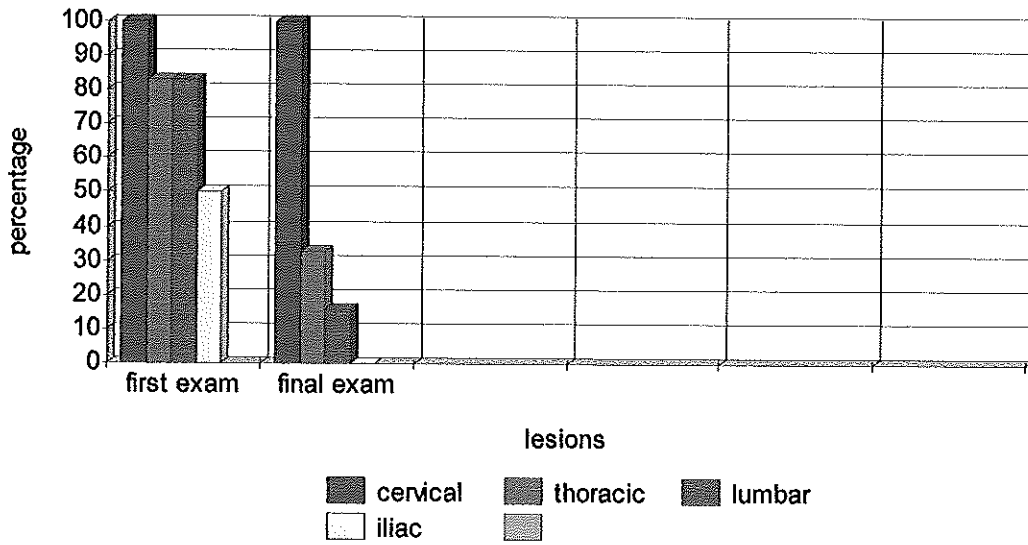
### RESULTS OF SECOND EXAMINATION



### RESULTS OF FINAL EXAMINATION



### Comparison of Lesions Found



## Discussion of Results

The results of the above research must be closely analysed in order to ascertain whether or not the results are considered to be those of good grounds. Before the research was collected some questions were asked based on the findings of the Literature Review. One question asked was, '**Does the use of choke chains increase the risk of damage to the cervical region?**'. The research done would indeed agree that the use of choke chains does in fact cause damage to the cervical region. This could be proved by the fact that all six dogs used for the research had cervical lesions, many of these lesions were lower cervical lesions which is the location that the choke chain sits on the dogs neck. Another interesting factor was that most dogs had a reduction in their ROM to the right. It would be consider that this is because dogs are constantly pulling away from their owners causing muscular contraction of the muscles on the left side of the neck. During the research it was noted that some dogs had a tendency to carry the head to the right as they were lead from their owners left hand side, this would have surely expected to turn up the result of the ROM being reduced to the left not the right as the dog is kept a tight hold of by its owner. Is the ROM reduced to the right because although the dog is being walked with its head held to the right by the owner the dog is in fact resisting this and therefore tensing the muscles of the left side still?. This result could however be further challenged as no dogs were looked at that had been walked using an alternative to choke chains. Another point that could be made is that only six dogs were used and that maybe this was too smaller number to get an accurate result. '**Some training methods have the**

**dog look to its right and up to its owner or trainer. This causes unilateral muscle spasms and a sore neck' (Dr Daniel Kamen, The Well Adjusted Dog).**

Another question asked was **'Is there a relationship between the use of choke chains, cervical pathologies and excitable or nasty behaviour?'** As none of the dogs used in the research had a history of nasty behaviour that part of the question cannot be answered. As for the excitability there was some evidence shown by dogs A and B that after treatments their behaviour had calmed down. This behaviour did however seem to revert back to its original level within days of treatment. Could it be that because the dogs were continuing to be walked using the choke chains that the relief given by the osteopathic treatments was being reversed, as the choke chains were the problem factor and that the dogs were only behaving badly because they were in pain?. Dog F would then make this theory questionable as it didn't behave badly at all on the lead and probably didn't need to be walked using a choke chain, however Dog F did have a mid cervical lesion. This lesion could be argued was due to the sore area between the digits of its left fore limb, and maybe its good behaviour too as the foot was too sore for any bad behaviour. Or did the dog just have a placid temperament?.

Osteopathic treatment proved to be hugely successful in the treatment of the many lesions found in the six dogs used in this research. So when asking the question **'Are the cervical pathologies found in dogs, associated with the use of choke chains, rectified with osteopathic treatment?'**, Looking at the above data it would conclude that while osteopathic treatment showed great results with regard to the cervical lesions present in

the dogs, it cannot claim to have completely rectified them as 100% of the dogs still had cervical lesions present at the time of the final examination. Was the presence of these lesions due to the continued use of the choke chains after treatment?. Was the presence of these lesions due to another cause?. For example, the dogs had been involved in some kind of accident during the course of the treatment, or maybe that where the dogs lived together and played together that rough play was the culprit of these lesions. **'Maybe you played too hard today with the Frisbee and caused your dogs to jump too high, causing neck pain. The important thing is to try to correct possible activities that may cause neck subluxations.'**(Rose Smith, DogTrainingAdvice.com, 2005).

Sometimes two dogs who live together and are very good friends can play very rough and over exert themselves possibly causing themselves damage.

Another avenue for investigation would be the dogs sleeping arrangements as an association between a dog with an uncomfortable and non supportive bedding and cervical lesions is documented by Dr Daniel Kamen **'Dogs should get used to one comfortable place to sleep,preferably a flat surface with moderately firm padding, like a wrestling mat. Studies have shown that dogs need support when they are sleeping, as do people'**. (Dr Daniel Kamen, The Well Adjusted Dog). Dr Daniel Kamen also talks about the relationship between caged dogs and subluxations, **'Where there is no room to move around there is no way to relieve muscular stress'**. (Dr Daniel Kamen, The Well Adjusted Dog).' Could this be the reason that dogs A and B were so badly behaved?, being kept in a kennel together where they wouldn't have had enough room to release muscular tension and then when they were allowed out, twice



daily for a 45 minute walk they were beside themselves with excitement and anxiety and so appeared to have very bad manners. Another issue which Dr Daniel Kamen talk about is the relationship between the length of the leash and postural problems, **'Holding the dog too close with a short leash will limit the dogs stride and cause chronic postural problems.'** (Dr Daniel Kamen, *The Well Adjusted Dog*). This statement is agreed with by many others, one such person is Stan Rawlinson **'The lead should be at least 5 foot long irrespective of the size of the dog, this will help all training and lead work in the future'** (Stan Rawlinson, *Dog Behavioural Consultant*).

The final 'Research Question' asked was **'Do cervical pathologies reoccur in dogs if the use of a choke chain continues?'**. As 100% of the dogs researched still had cervical lesions at the stage of the final examination I would say that the continued use of the choke chains had a significant part to play in the continued presence of the cervical lesions as other lesion found in the dogs that were possible as a result of alternative traumas were resumed, i.e., the Ileum pathologies of dogs B and D. However as I did not partake in any research of dogs that were not walked using a choke chain this statement could be challenged.

Looking at Dr Daniel Kamens statements in relation to the results of my research I can find some correlation such as the 'caged dog' statement in relation to dogs A and B. I also found that two of the six dogs, 33%, were still experiencing pathologies in the thoracic regions at the stage of the final treatment these pathologies are also associated with the harsh use of choke chains. I noticed that dog C had a small bed in relation to its size and that it had a pile of uneven blankets to lay on and laid with its head over the side

that he felt that choke chains should carry a warning and that when he asked a number of trainers **'Seven thought it might be a good idea to add a warning label to each chain at the point of sale'**. I agree that warnings should be issued if people choose to use choke chains or that an alternative method of training be advised, maybe a reward based training regime where the dog is prepared to stay by your side because you are the nice person with the pocket full of treats. **'Do not rely on your lead to control your dog. It is the least reliable form of control. If you accidentally drop the lead or it breaks then you will probably loose your dog. If he rarely ever feels pressure around his neck then he would not be aware and would continue to walk beside you anyway'**. (Lead Training-Walking on a loose lead, Scallywags.com, 2006).

As I do believe that choke chains are the cause of cervical lesions which cause great pain to the dogs I believe that a huge amount of dogs that pull uncontrollably on the lead do so because they are trying to run from the pain, unknown to them they are in fact causing themselves more damage, pain and discomfort. This is the opposite effect to that which the owner intends to achieve. It is also possible with harsh use of a lead to cause the other end of the scale **'The relentless and violent training use of choke chains can cause a dog to become fearful of hands, resentful and aggressive; the opposite effect owners hope to accomplish with training'** (Choke Chains Not Always Effective Tool, Diane. L. Jarvis).

The fact that 100% of the dogs in my research showed cervical lesions was a good statistic, however it could be argued that not enough dogs were used for the research and

that he felt that choke chains should carry a warning and that when he asked a number of trainers **'Seven thought it might be a good idea to add a warning label to each chain at the point of sale'**. I agree that warnings should be issued if people choose to use choke chains or that an alternative method of training be advised, maybe a reward based training regime where the dog is prepared to stay by your side because you are the nice person with the pocket full of treats.**'Do not rely on your lead to control your dog. It is the least reliable form of control. If you accidentally drop the lead or it breaks then you will probably loose your dog. If he rarely ever feels pressure around his neck then he would not be aware and would continue to walk beside you anyway'**. (Lead Training-Walking on a loose lead, Scallywags.com, 2006).

As I do believe that choke chains are the cause of cervical lesions which cause great pain to the dogs I believe that a huge amount of dogs that pull uncontrollably on the lead do so because they are trying to run from the pain, unknown to them they are in fact causing themselves more damage, pain and discomfort. This is the opposite effect to that which the owner intends to achieve. It is also possible with harsh use of a lead to cause the other end of the scale **'The relentless and violent training use of choke chains can cause a dog to become fearful of hands, resentful and aggressive; the opposite effect owners hope to accomplish with training'** (Choke Chains Not Always Effective Tool, Diane. L. Jarvis).

The fact that 100% of the dogs in my research showed cervical lesions was a good statistic, however it could be argued that not enough dogs were used for the research and

therefore I didn't have a wide range of dogs with a wide range of behavioural levels, all the dogs used for this research were quite highly strung dogs that appeared to be missing some basic training and where it could be thought that the owners had indeed relied on the choke chains to install good manners only to find that the opposite effect had occurred. The reliability of the results collected from Dog F could also be questioned as it became apparent during the second examination that the dog was in fact suffering from an abscess between its second and third digits.

In conclusion I feel that the keeping and training of a dog is a very delicate area that needs to be looked into very carefully and advice of professionals should be sort in order to keep animals suffering to a minimum.

### **Applications and Limitations**

On the positive findings of my research, into the damage caused by the use of choke chains, I feel that it is vital that certain bodies are informed of the findings as the main issue involved is the welfare of the dogs. I would hope that my research along with other research already conducted would help to make the dangers of the use of choke chains more apparent. In order for this to happen I feel that Veterinarians, Osteopaths, owners, lead companies and welfare establishments should have access to such studies and statistics.

During the course of my research it was brought to my attention that there could be some factors present that may have hindered the results of my research, these were:

- That a larger number of dogs would have given a more accurate result.
- That I was not there to monitor walkings and therefore had to take the owners word that they had walked the dog using the choke chain and that they had walked the dog at least three times a week.
- The fact that 33% of the dogs slept outside in a kennel while 67% lived in the house.
- That the dogs had a variety of bedding arrangements i.e. some had round beds while others had flat mattress types and some had blankets.

Some dogs had their choke chains put onto their necks as well as their collars which they wore all the time while others did not wear a collar.

### **Areas of Future Research**

The highlighted areas above show that before initiating any research many factors need to be taken into account in order to make a fair conclusion of the research results. This is a very important consideration as it must be the method of restraint that is being investigated into and therefore as much as possible the method of restraint that is turning up results and not other outside factors. With areas of further research in mind I consider that my research has barely scraped the surface and that there is a demand for knowledge

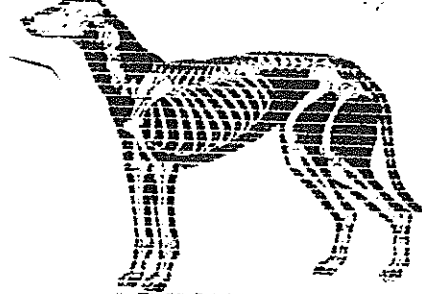
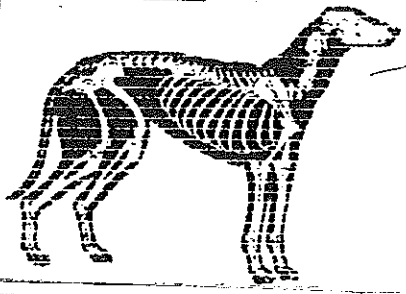


**ANITA MILES**  
Animal Manual Therapist

EUROPEAN SCHOOL  
OF ANIMAL OSTEOPATHY LTD  
25 OLD STEINE  
BRIGHTON  
BN1 1EL

TEL: +44 1273 673 332  
FAX: +44 1273 673 339

Owners Name: .....	Animal Name: .....
Address: .....	Age: ..... Type: .....
.....	Sex: ..... Colour: .....
Tel No: ..... Date: .....	Vet: .....



<b>HISTORY:</b>
<b>DYNAMICS:</b>
<b>PALPATION:</b>
<b>TREATMENT:</b>
<b>RECOMMENDATIONS:</b>

# QUESTIONNAIRE

1. DOG NAME?.....
  2. DOG AGE?.....
  3. DOG BREED?.....
  4. DOG JOB?.....
  5. WHAT DOES THE DOG EAT?.....
  6. DOES THE DOG PULL ON THE LEAD?.....
  7. HOW OFTEN IS DOG WALKED?.....
  8. WHAT TYPE OF LEAD IS USED?.....
  9. HAS THE DOG EVER BEEN WALKED USING ANY OTHER TYPE OF  
LEAD?.....
  10. WHERE IS THE DOG WALKED?.....
  11. WHERE DOES THE DOG SLEEP?.....
  12. WHAT TYPE OF BED AND BEDDING DOES THE DOG HAVE?  
.....
  13. HAS THE DOG HAD ANY PREVIOUS ACCIDENTS?  
.....
  14. MEDICAL HISTORY.....
  15. IS AGGRESSIVE OR EXCITABLE BEHAVIOUR SHOWN?.....
- NOTES.....

and statistics in the area of damage caused by methods of restraint in dogs. Therefore I believe it would be beneficial to investigate into many different types of restraint. There also needs to be some investigations done into the methods of training using the restraints and the damage that bad training practices cause.

### **Conclusion**

From my research I conclude that there is an association between the use of choke chains and cervical and thoracic lesions. I also feel that an association between bad or over excitable behaviour and the use of choke chains is clear. My findings show that an alternative method of training should be sort and that owners need to be trained how to gain the obedience of their dogs and that punishment methods don't have a high success rate.

My research showed that osteopathic treatment had incredible results with regard to lesions that were not primarily caused by the use of the choke chains, i.e. the dog had had another traumatic experience. I also had reports of improvements in coat condition; general activity and energy levels owing to the treatments.